

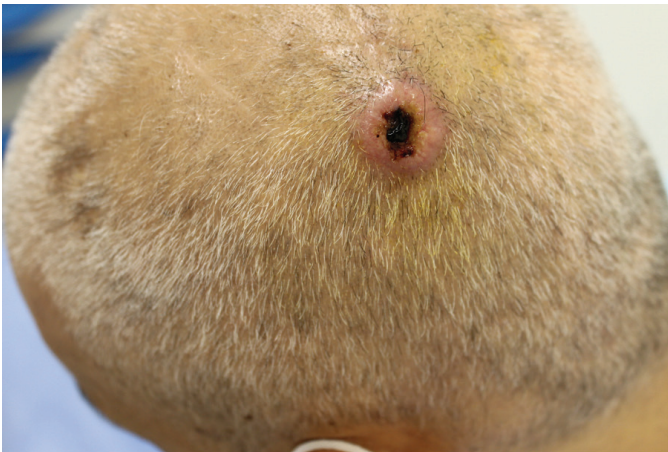# A Solitary Nodule on the Scalp: An Unusual Presentation of Metastatic Colorectal Carcinoma

© Ahmet Faruk Tari<sup>1</sup>, © İlteriş Oğuz Topal<sup>1</sup>, © Yavuz Semiz<sup>1</sup>, © Mehmet Alp Matur<sup>1</sup>, © Özben Yalçın<sup>2</sup>

<sup>1</sup>University of Health Sciences Turkey, Prof. Dr. Cemil Taşcıoğlu City Hospital, Clinic of Dermatology, İstanbul, Turkey

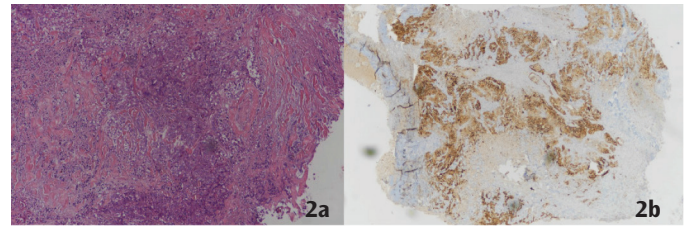
<sup>2</sup>University of Health Sciences Turkey, Prof. Dr. Cemil Taşcıoğlu City Hospital, Clinic Pathology, İstanbul, Turkey

**Keywords:** Cutaneous, metastasis, nodule



**Figure 1.** A 52-year-old male patient applied to our clinic because of a hard mass on the scalp. It was learned that the patient had been in follow-up for two years for colorectal adenocarcinoma in the oncology clinic and was undergoing chemotherapy treatment after the surgical operation.

An examination of his scalp revealed a solitary, hard, infiltrated, hemorrhagic erythematous nodule with hemorrhagic crust in the middle with a diameter of about 1 cm.



**Figure 2.** A 4 mm punch biopsy sample was obtained from the lesion. Biopsy showed cells with atypical malignant properties (Figure 2a). Immunohistochemical examination was determined as CK20(+), CDX2(+), CK7(-) and TTF-1(-) (Figure 2b). With these findings, the patient was diagnosed with skin metastasis.

Cutaneous metastasis is extremely rare in internal malignancies. It is usually an indicator of advanced disease and is associated with poor prognosis (1). Colorectal carcinoma is an important source of cutaneous metastases due to its high incidence in society. However, colorectal carcinomas have a low risk of cutaneous metastasis and are found in an average of 4% of cases (2). Lesions are most commonly found on the abdominal area skin. It is extremely rare to be seen in other regions (3). Clinicians should consider the possibility of metastasis and conduct the necessary examinations and tests if the patient also has an oncological history when faced with hard, infiltrated lesions with atypical localization.



**Address for Correspondence:** Ahmet Faruk Tari, University of Health Sciences Turkey, Prof. Dr. Cemil Taşcıoğlu City Hospital, Clinic of Dermatology, İstanbul, Turkey

**Phone:** +90 530 414 20 84 **E-mail:** drahmettari@gmail.com **ORCID ID:** orcid.org/0000-0001-6759-2678

**Cite this article as:** Tari AF, Topal İO, Semiz Y, Matur MA, Yalçın Ö. A Solitary Nodule on the Scalp: An Unusual Presentation of Metastatic Colorectal Carcinoma. Eur Arch Med Res 2022;38(2):152-153

©Copyright 2022 by the University of Health Sciences Turkey, Prof. Dr. Cemil Taşcıoğlu City Hospital  
European Archives of Medical Research published by Galenos Publishing House.

**Received:** 12.11.2021

**Accepted:** 02.04.2022

**Ethics**

**Informed Consent:** Informed consent was obtained.

**Peer-review:** Externally peer-reviewed.

**Authorship Contributions**

Surgical and Medical Practices: A.F.T., İ.O.T., Y.S., M.A.M., Ö.Y., Concept: A.F.T., İ.O.T., Design: A.F.T., İ.O.T., Data Collection or Processing: A.F.T., İ.O.T., Ö.Y., Analysis or Interpretation: A.F.T., İ.O.T., Y.S., Literature Search: A.F.T., İ.O.T., Y.S., Writing: A.F.T., İ.O.T.

**Conflict of Interest:** No conflict of interest was declared by the authors.

**Financial Disclosure:** The authors declared that this study received no financial support.

**REFERENCES**

1. Liao L, Cheng Q, Zhu G, Pei F, Ye S. Cutaneous metastasis of ascending colon cancer harboring a BRAF V600E mutation: A rare case report. *Medicine (Baltimore)* 2020;99:e20026.
2. Malla S, Razik A, Vyas S. Cutaneous metastasis in adenocarcinoma rectum. *BMJ Case Rep* 2019;12:e229652.
3. Wang DY, Ye F, Lin JJ, Xu X. Cutaneous metastasis: a rare phenomenon of colorectal cancer. *Ann Surg Treat Res* 2017;93:277-80.